

# Research Journal of Pharmaceutical, Biological and Chemical Sciences

## A Rare Presentation of Ascending Colon Growth.

Arvind Gilbert J\*, Keerthy Sagar Reddy, RNM Francis, P Darwin, CT Karthikeyan, and P Inbaselvi.

Sree Balaji Medical College & Hospital, Bharath University, Chrompet, Chennai – 600044, Tamil Nadu, India.

### ABSTRACT

This case is being presented as the patient(60 year old male) manifested with pain upper abdomen and vomiting on and off for 3 months duration associated with history of loss of weight/appetite, malena, altered bowel habits and jaundice. Clinically two possibilities were thought of – Gall bladder malignancy or transverse colon growth with liver secondaries. Colonoscopy revealed an ulcero-proliferative growth in the ascending colon with luminal narrowing. Biopsy taken from lesion came back as moderately differentiated infiltrating mucin secreting Adenocarcinoma of ascending colon.

**Keywords:** colon, abdomen, jaundice.

*\*Corresponding author*

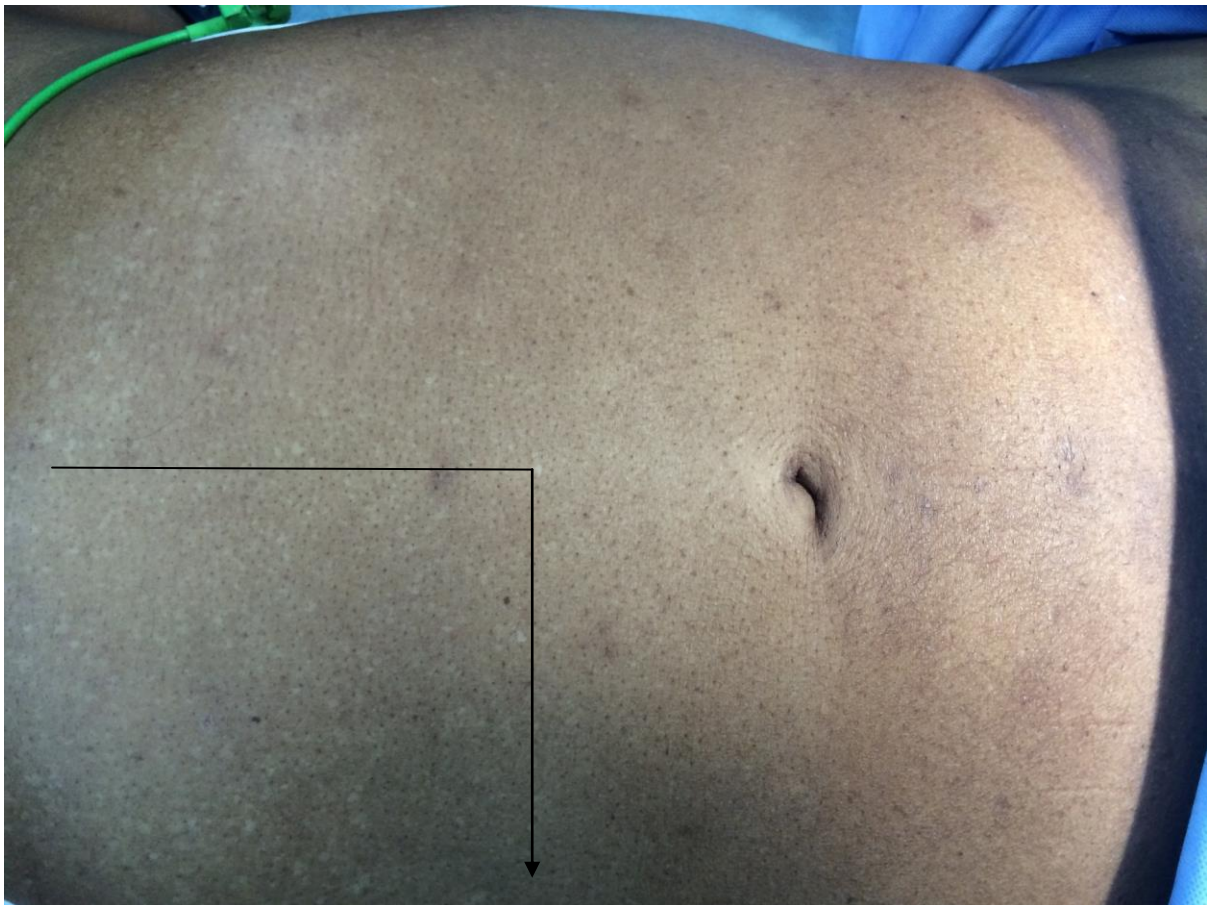
**CASE REPORT:**

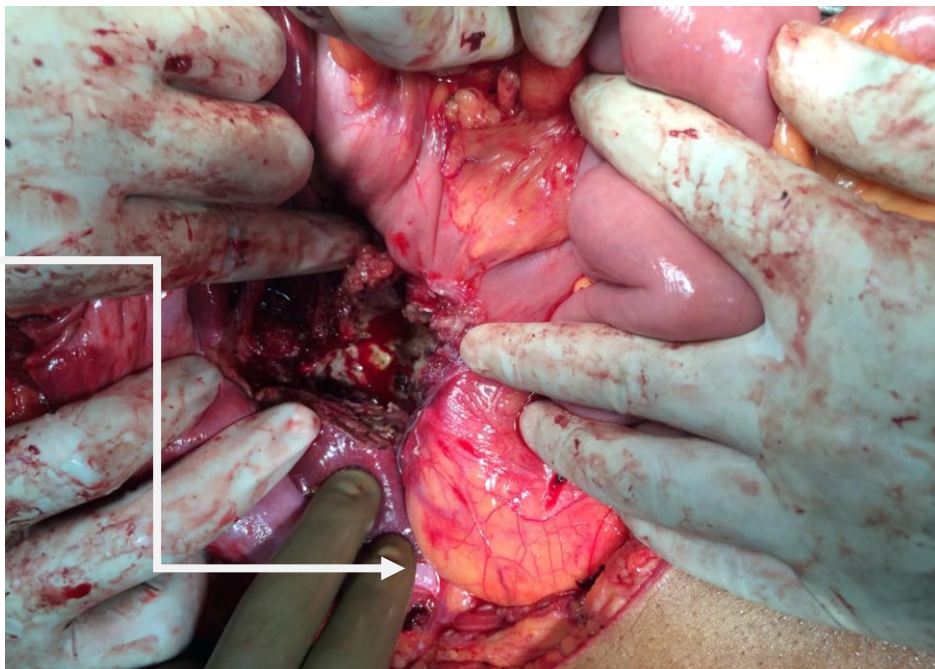
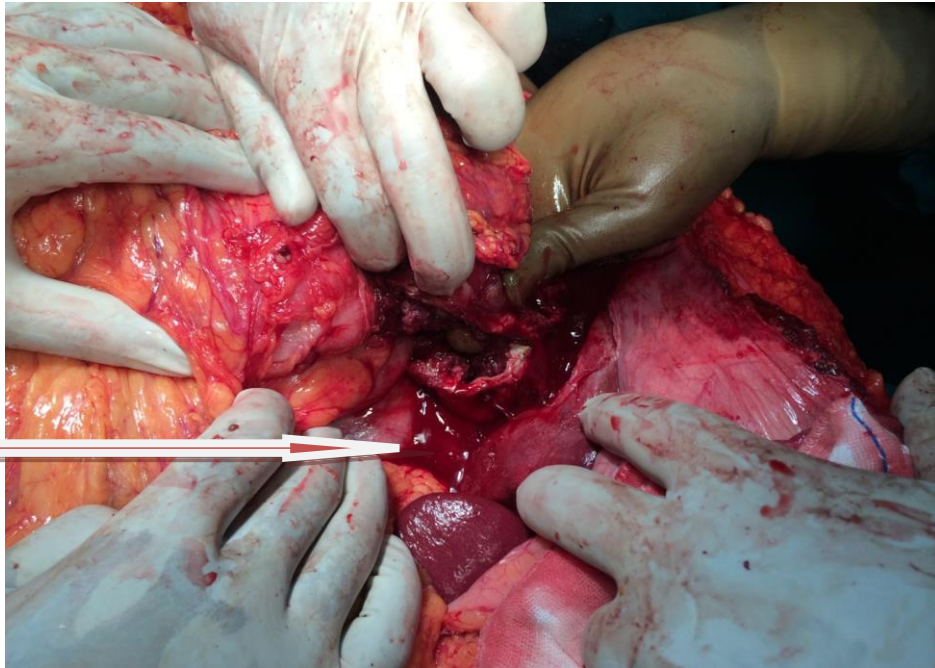
60 year old male came with complaints of pain upper abdomen with vomiting on and off X 3 months duration. H/o loss of weight/appetite and jaundice present. Patient also gave h/o malena and altered bowel habits. No h/o fever and bone pain. O/E : Patient moderately built and nourished, no palor, icterus or pitting pedal edema. Per Abdomen : soft, a 7 \* 5 cm mass was palpable in the right hypochondrium firm in consistency, moving with respiration, mild hepatomegaly (+),No free fluid, bowel sounds were heard.DRE : NAD. Contrast enhanced CT Abdomen revealed a heterogenous mass lesion in the gall bladder fossa involving adjacent inferior surface of liver parenchyma, second part of duodenum and hepatic flexure. CEA: 10.59 ng/ml. Colonoscopy showed a circumferential ulceroproliferative growth in ascending colon with luminal narrowing. Biopsy taken from lesion came back as moderately differentiated infiltrating mucin secreting Adenocarcinoma of ascending colon. Patient was prepared for surgery (laparotomy/proceed)

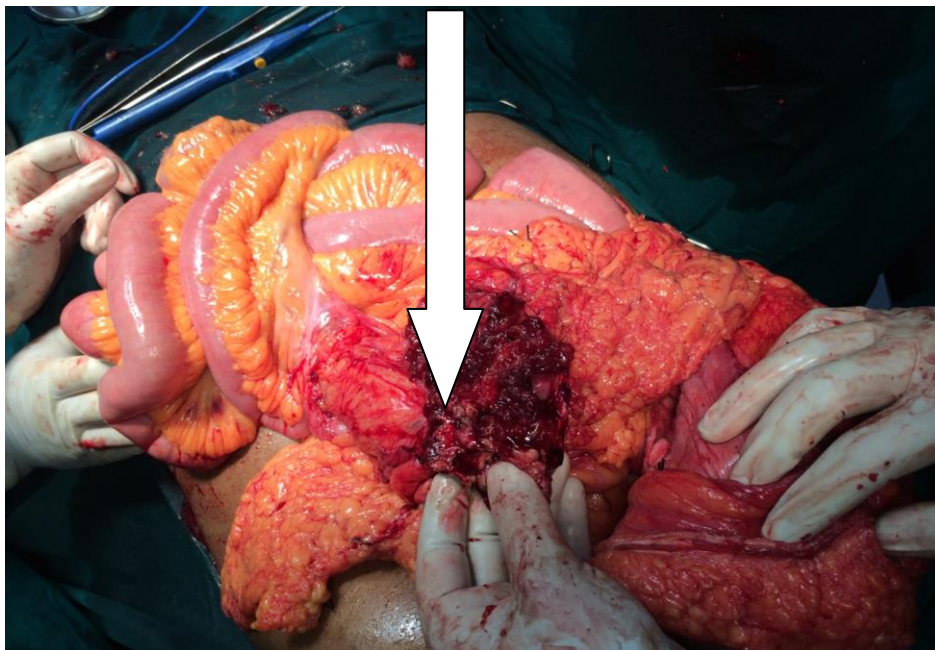
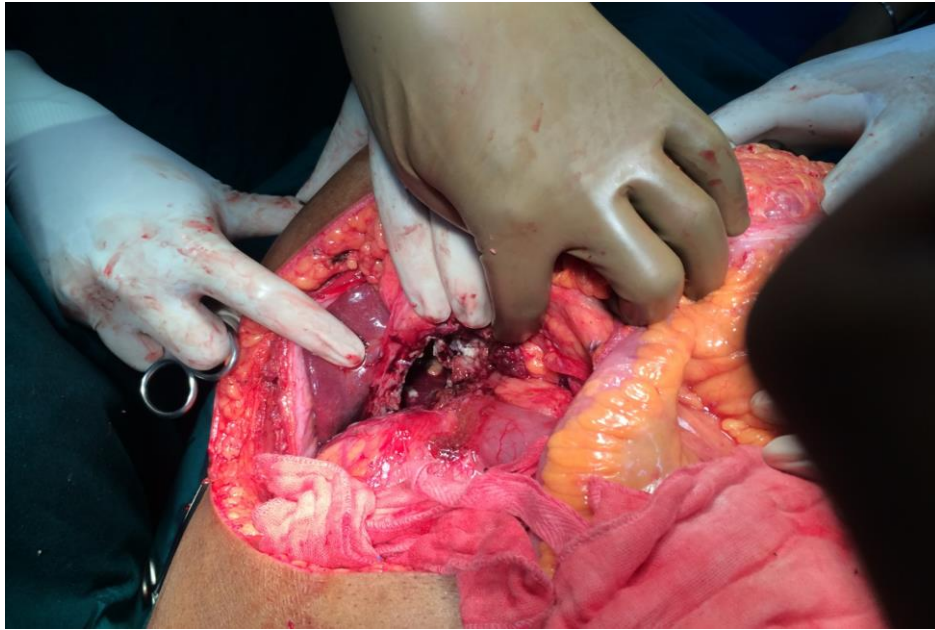
**Per operative findings:**

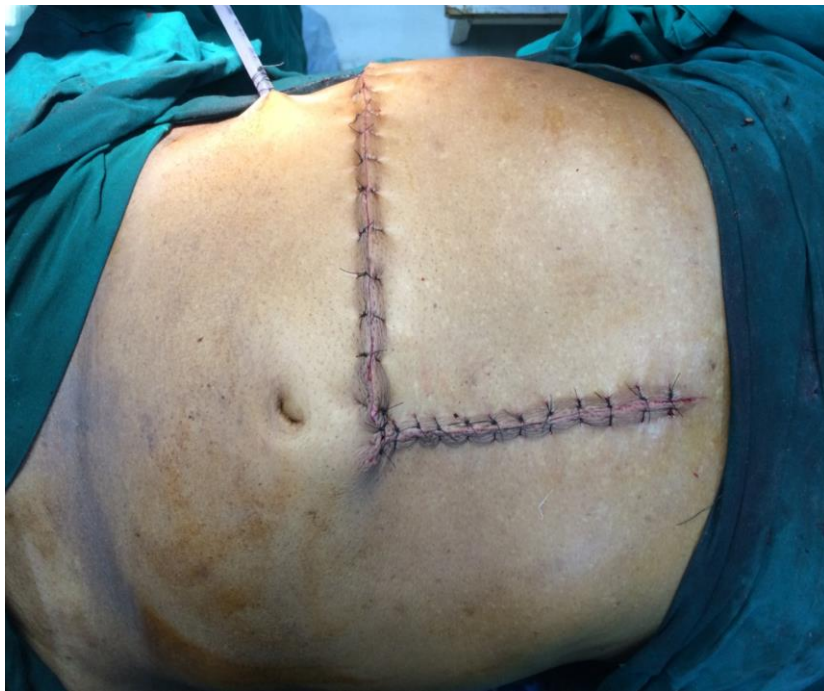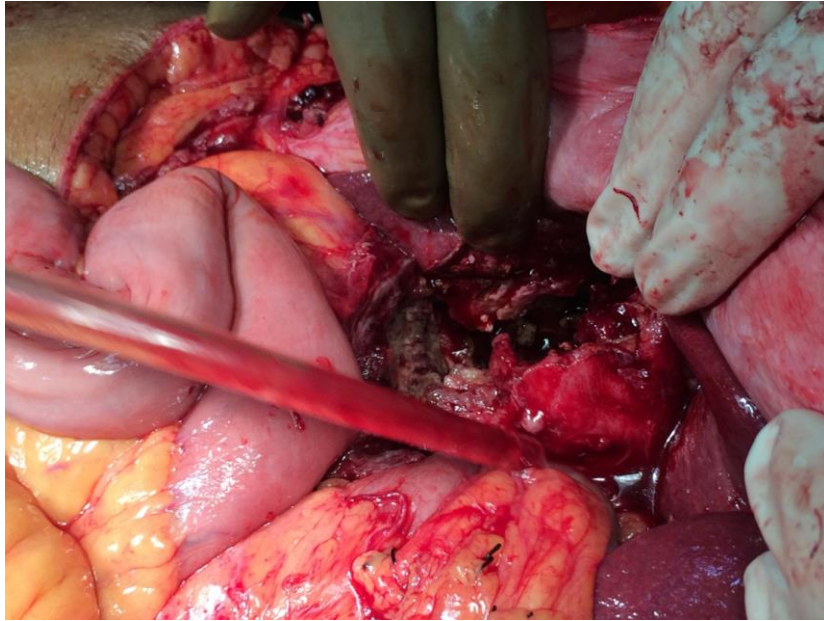
- Growth ascending colon infiltrating the inferior surface of right lobe of liver and gall bladder. No duodenal infiltration.
- Retrocolic Abscess(+)
- Deposits in the falciform ligament and right paracolic gutter.

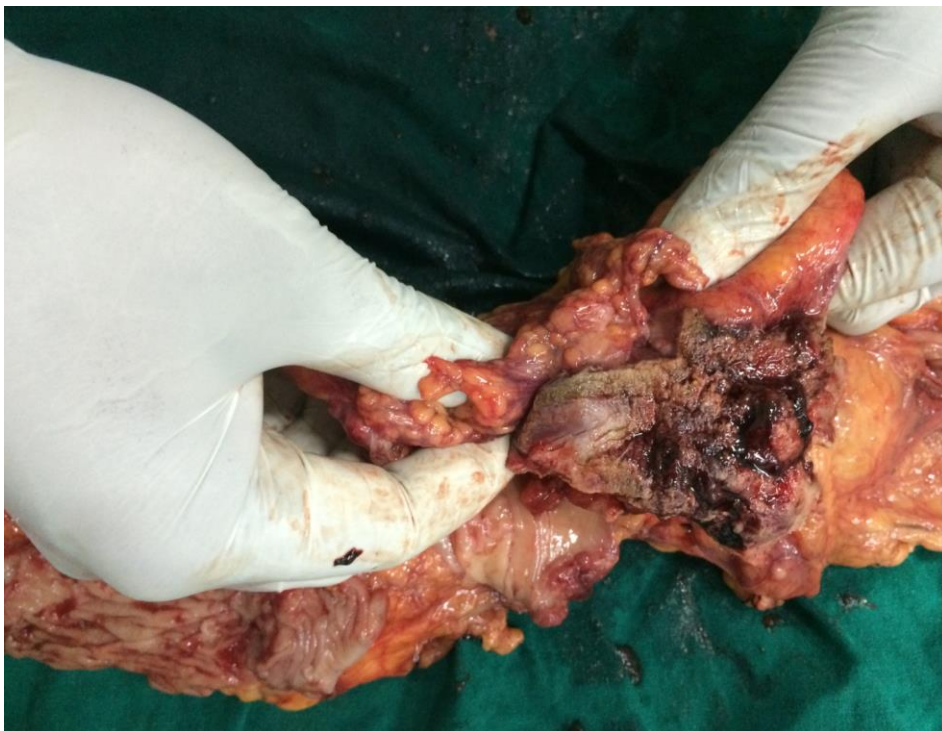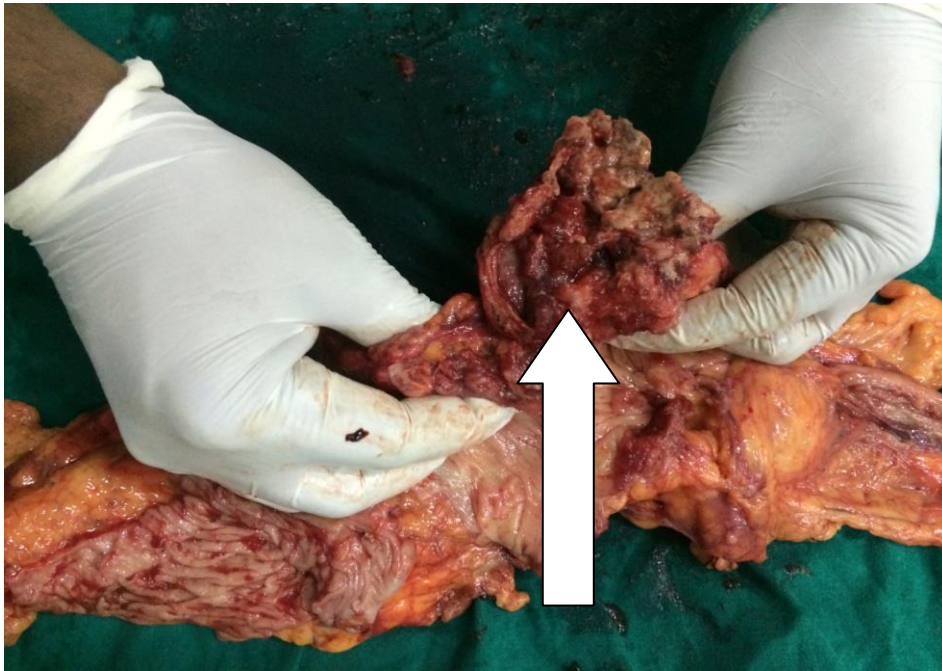
Abscess cavity was curreted and drained. Subtotal cholecystectomy along with portion of inferior surface of right lobe of liver done. Right radical hemicolectomy followed by end to side ileo- colic anastomosis was done. Resected specimens were sent for HPE. Immediate postoperative period was uneventful and the patient recovered well.











#### HPE REPORT

- Infiltrating mucin secreting adenocarcinoma of ascending colon.
- Resected margins normal.
- Deposit from falciform ligament –infiltration of tumor islands.
- Tissue from right paracolic gutter –free of tumor.

Serosal aspects of gall bladder and liver capsule shows adherent tumor tissue.

Immunohistochemistry: CK 20 positive, CDX2 negative.

Patient was subjected to chemotherapy, doing well and on periodic follow up.

### DISCUSSION

More than 90% of colonic malignancies are ADENOCARCINOMAS (histologically). Risk factors include red /processed meat consumption, smoking, low dietary intake of calcium, dietary fibre and antioxidants (vitamin C, D and E), Inflammatory bowel disease, familial adenomatous polyposis (FAP) and hereditary nonpolyposis colorectal cancer (HNPCC)

Histopathologically: Ulcerative, Exophytic, Annular are the common variants. Others include mucinous (colloid), signet ring cell carcinoma, adenosquamous and squamous cell carcinoma.

Mucin secreting Adenocarcinoma is a subtype of colorectal carcinoma with mucin lakes comprising at least 50% of tumor mass. Relatively common (10% of all colorectal carcinomas) and most commonly arises in the right colon. *KRAS* mutations more common, and *TP53* mutations less common, than in standard colorectal carcinomas. Grossly it appears as exophytic, gelatinous mass. Histologically: Adenocarcinoma with strips of tumor cells floating in large extracellular mucin lakes comprising at least half of tumor mass. Immunohistochemistry: CDX2 (100%), MUC2 (100%), CK20 (98%), beta-catenin (nuclear) (64%), CK7 (19%, usually rectal), MUC6 (5%)

Clinical features include: Bleeding P/R, anemia, pain abdomen, altered bowel habits, anorexia, loss of weight, nausea, vomiting, fatigue.

Diagnosis is made via colonoscopy/biopsy and CEA levels. For staging work up Contrast enhanced CT Abdomen, LFT and Chest X ray is to be undertaken.

### MANAGEMENT

- SURGERY/CHEMOTHERAPY
- Primary surgical treatment is to eradicate disease in colon, draining nodal basins, venous and arterial supply and contiguous organs.
- Stage of the disease, presence of synchronous colonic tumors and underlying colorectal cancer syndromes are significant factors in determining optimal surgical approach
- ✓ 5 Fluorouracil, Leucovorin and Oxaliplatin are the chemotherapeutic agents employed.
- ✓ Radiotherapy has no primary role in the adjuvant treatment of colon cancer.

### Prognosis

- 5 year survival rate for all stages is 64%
- Node involvement is the primary determinant of 5 year survival.
- T 1 and T 2 with node negative: 90% 5 year survival and 80% for T3 lesions.
- For node positive disease 5 year survival ranges from 74 % with N1 disease to 51% with N2 disease.
- Tumor grade, bowel perforation and obstruction are other prognostic indicators.

### CONCLUSION

Early stage of colonic malignancy (stage 1 and 2) have better outcomes compared to advanced disease which carries a poor prognosis with respect to 5 year survival.

Surgery remains the gold standard of treatment followed by chemotherapy.



**REFERENCES**

- [1] <http://www.rsna.org/REG/publications/rg/afip/privateM/1995/0015/0001/0127/1.htm>.
- [2] Okuyama, Takashi and Oya, Masatoshi. Japanese Journal of Clinical Oncology 2002;32:10
- [3] Symonds DA, Vickery AL. Cancer 1976;37:1891–1900.
- [4] Melis M, Hernandez J, Siegel EM et al. Dis Colon Rectum 2010;53:936–943
- [5] Chiang JM, Yeh CY, Changchien CR. et al. Int J Colorectal Dis 2010;25:941–947.
- [6] Nozoe T, Anai H, Nasu S, Sugimachi K. J Surg Oncol 2000;75:103–107
- [7] Leopoldo, S., Lorena, B., Cinzia, A. et al. Ann Surg Oncol 2008;15:1429–1439
- [8] Sobin LH, Fleming ID. Cancer 1997;80:1803–1804.
- [9] Papadopoulos VN, Michalopoulos A, Netta S. et al. Tech Coloproctol 2004;8:s123–s125
- [10] Hanski, C. Br J Cancer 1995;72:1350–1356.